

2023-09-15 11:26:26

Name : le koemchhun

Sex : Female Age : 80

Section: 1

RoomID:

BedID:

ID:

Operator: hh

Custom1:

Custom2:

Custom3:

Data for reference only:

HR bpm : 83

PR Interval ms : 212

P Duration ms : 120

QRS Duration ms : 92

T Duration ms : 213

QT/QTc ms : 419/493

P/QRS/T Axis deg : 67.8/50.9/59.3

R(V5)/S(V1) mV : 0.91/0.74

R(V5)+S(V1) mV : 1.64

<< Conclusions >>

Cardiac electric axis normal;

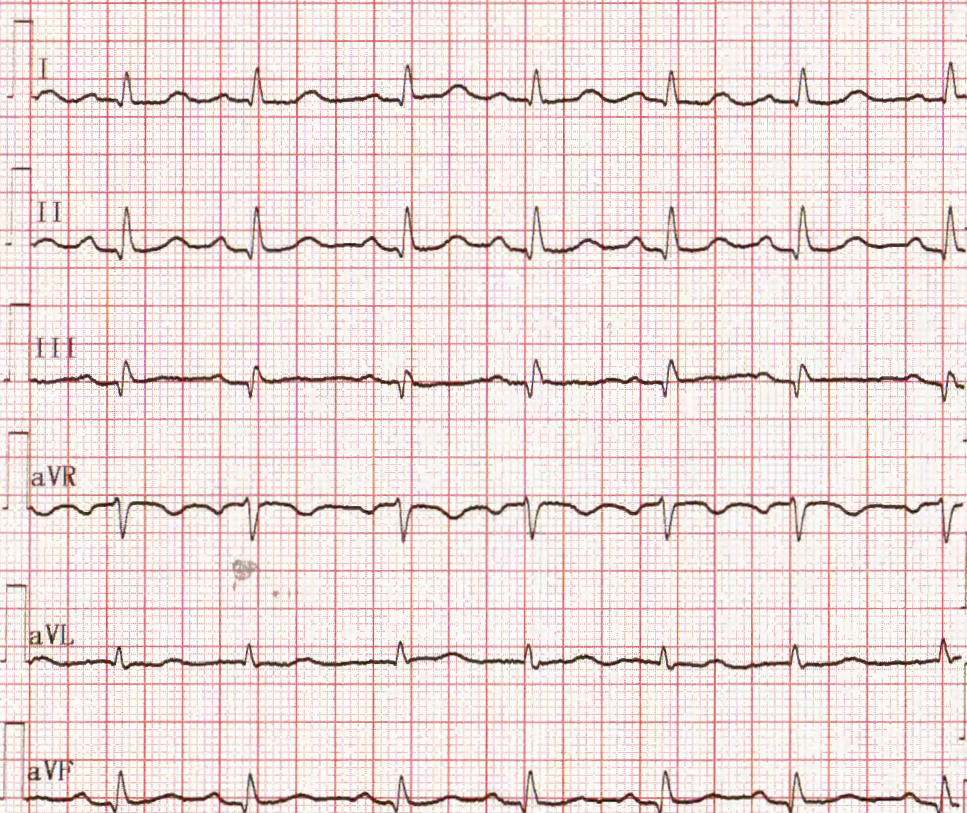
I AV block;

possible old inferior MI.

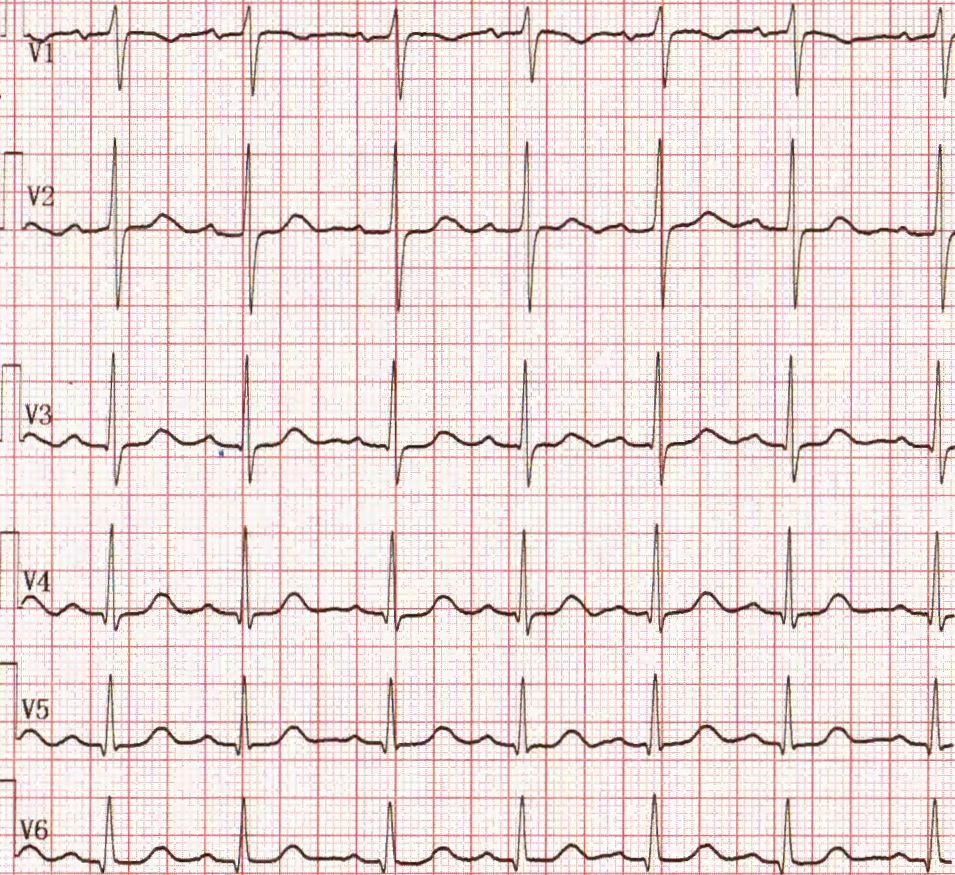
****Report need physician confirm****

Physician:

AUTO 10mm/mV



10mm/mV



II 10mm/mV

