

2023-09-25 10:40:44

Name :thim phanny

Sex :Female Age :66

Section: 1

RoomID:

BedID:

ID:

Operator: hh

Custom1:

Custom2:

Custom3:

Data for reference only:

HR bpm : 61

PR Interval ms : 207

P Duration ms : 120

QRS Duration ms : 79

T Duration ms : 227

QT/QTc ms : 442/446

P/QRS/T Axis deg : 43.4/52.8/60.3

R(V5)/S(V1) mV : 1.29/0.93

R(V5)+S(V1) mV : 2.22

<< Conclusions >>

Cardiac electric axis normal;

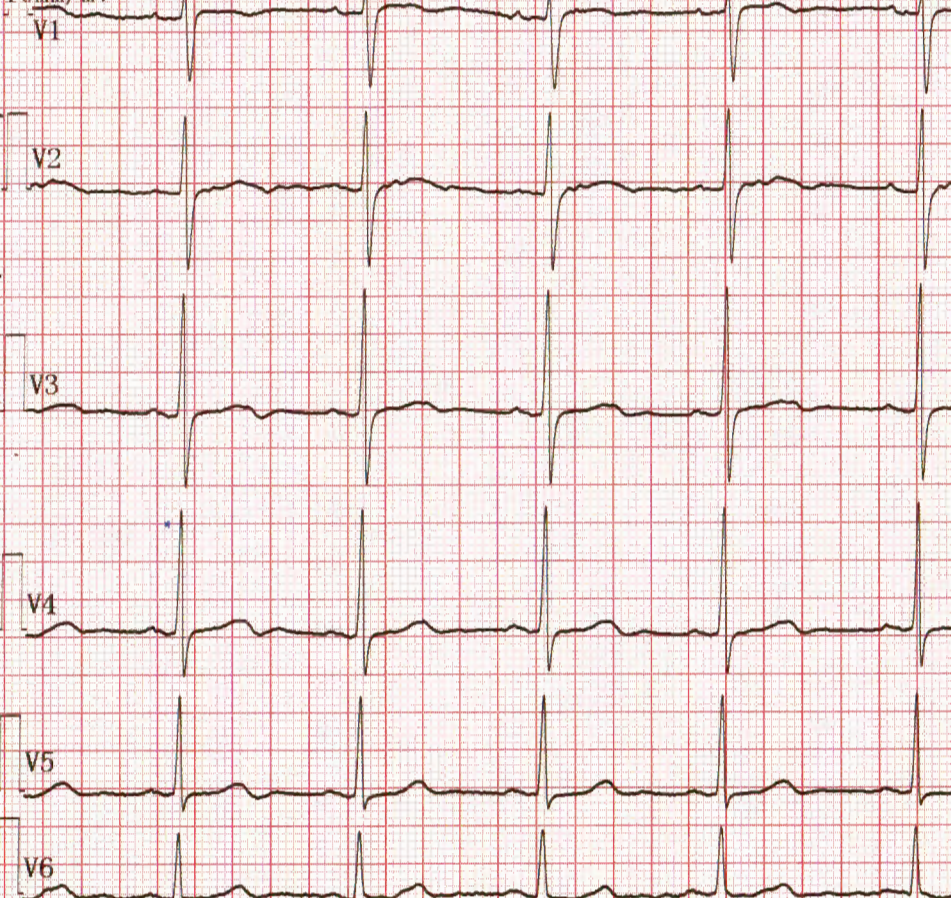
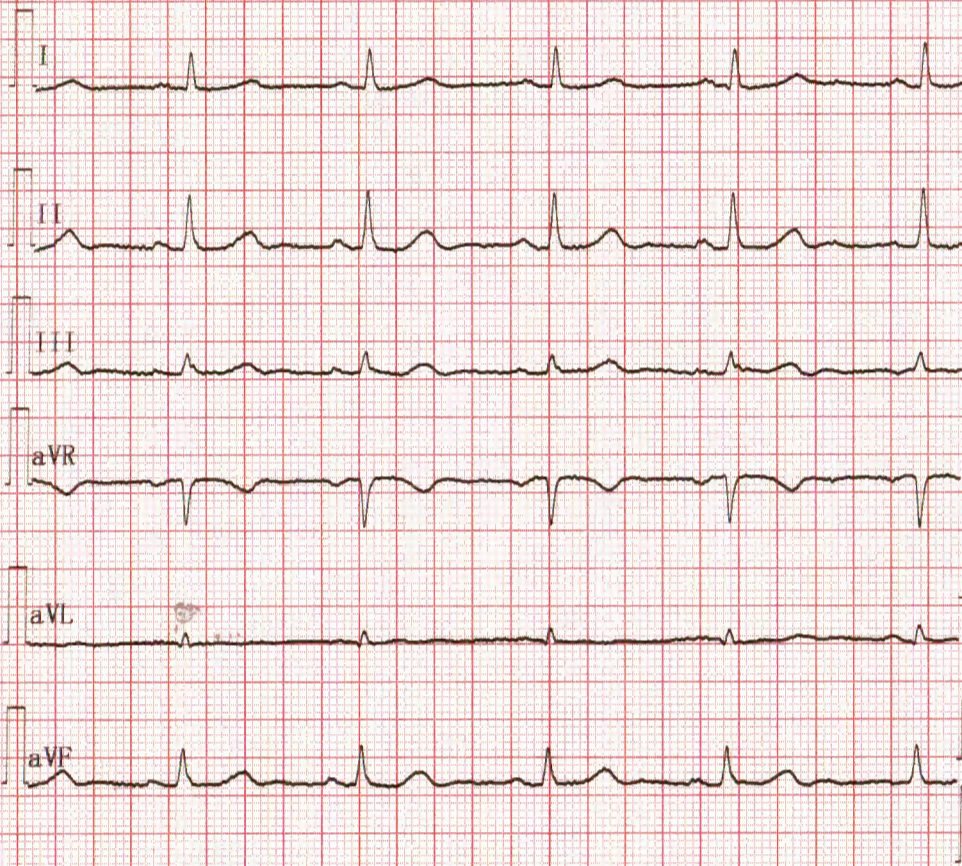
aVL V3 V4 Abnormal T wave;

****Report need physician confirm****

Physician:

AUTO 10mm/mV

10mm/mV



II 10mm/mV

25mm/s EMG25Hz+DFT0.5Hz