

2023-10-28 09:48:38

Name : te senghok

Sex : Male Age : 47

Section: 1

RoomID: _____

BedID: _____

ID: _____

Operator: hh

Custom1: _____

Custom2: _____

Custom3: _____

Data for reference only:

HR bpm : 63

PR Interval ms : 179

P Duration ms : 117

QRS Duration ms : 81

T Duration ms : 210

QT/QTc ms : 401/412

P/QRS/T Axis deg : 19.6/40.2/26.2

R(V5)/S(V1) mV : 1.84/0.55

R(V5)+S(V1) mV : 2.38

<< Conclusions >>

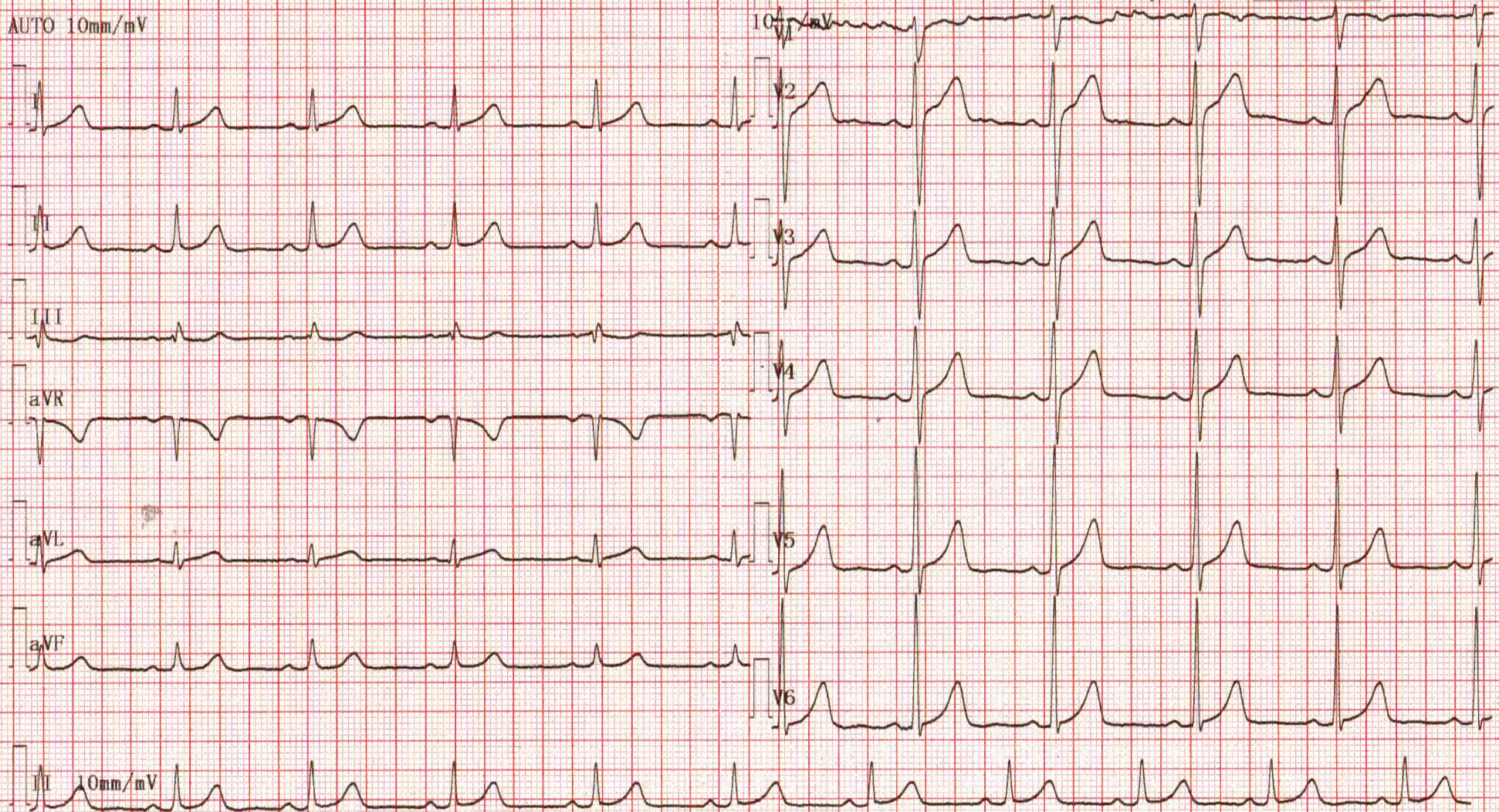
Normal Sinus Rhythm,

Cardiac electric axis normal,

****Report need physician confirm****

Physician: _____

AUTO 10mm/mV



25mm/s EMG25Hz : DFT0. 5Hz