

2024-01-03 08:37:14

Data for reference only:

<< Conclusions >>

Name : HEANG SAROM

Sex : Female Age : 51

Section: 1

RoomID: _____

BedID: _____

ID: _____

Operator: hh

Custom1: _____

Custom2: _____

Custom3: _____

HR bpm : 71
PR Interval ms : 194
P Duration ms : 116
QRS Duration ms : 72
T Duration ms : 213
QT/QTc ms : 385/417
P/QRS/T Axis deg : 45.2/40.0/5.6
R(V5)/S(V1) mV : 1.12/0.61
R(V5)+S(V1) mV : 1.73

Normal Sinus Rhythm;

Cardiac electric axis normal;

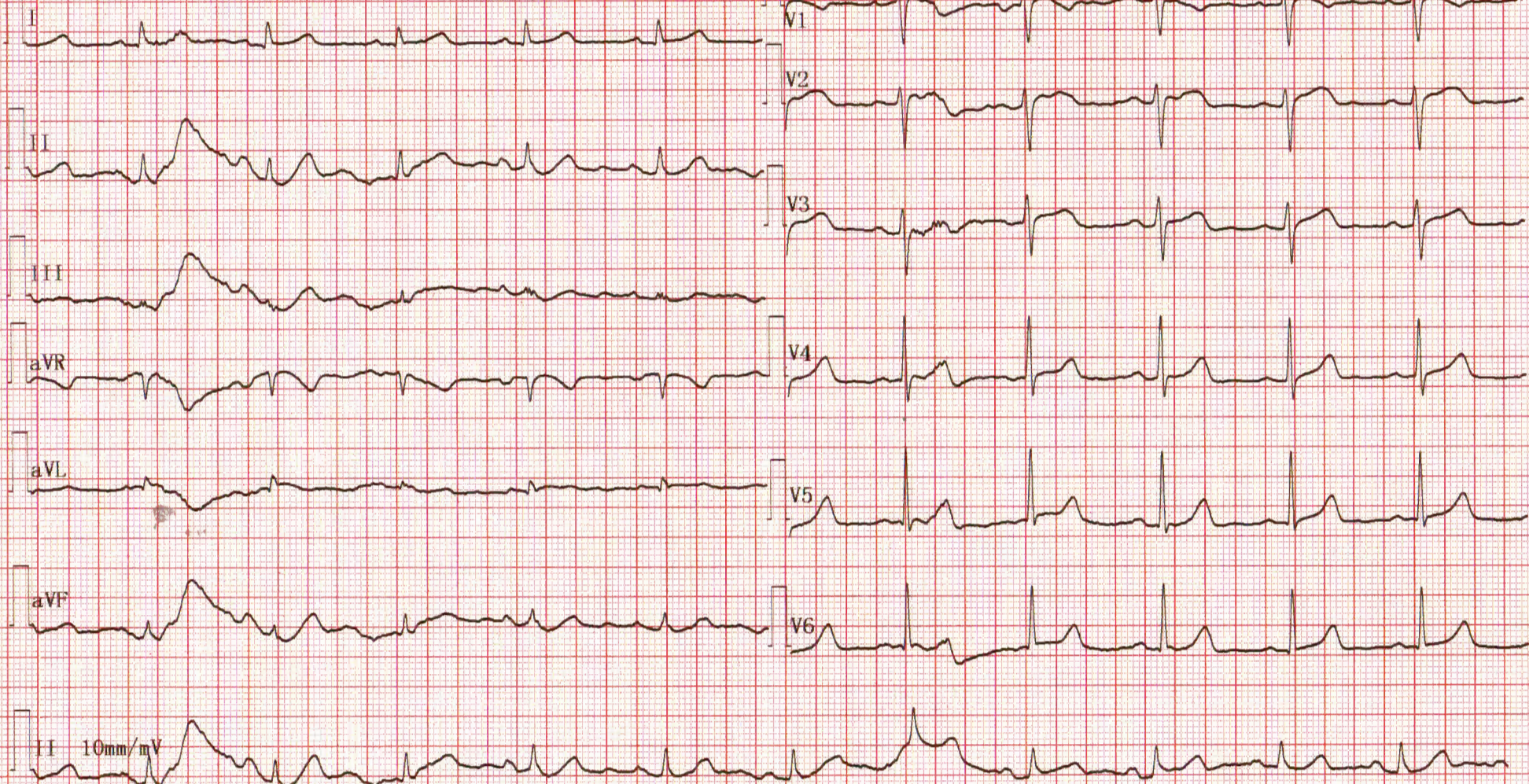
ST depression, possible mild inferior myocardial ischemia.

****Report need physician confirm****

Physician: _____

AUTO 10mm/mV

10mm/mV



25mm/s EMC25Hz+DFT0.5Hz