

2024-01-27 08:12:06

Name :din thol

Sex :Female Age :78

Section: 1

RoomID:

BedID:

ID:

Operator: hh

Custom1:

Custom2:

Custom3:

Data for reference only:

HR bpm : 83

PR Interval ms : 130

P Duration ms : 115

QRS Duration ms : 80

T Duration ms : 203

QT/QTc ms : 385/453

P/QRS/T Axis deg : 61.6/33.4/91.1

R(V5)/S(V1) mV : 1.84/0.68

R(V5)+S(V1) mV : 2.52

<< Conclusions >>

Normal Sinus Rhythm,

Cardiac electric axis normal,

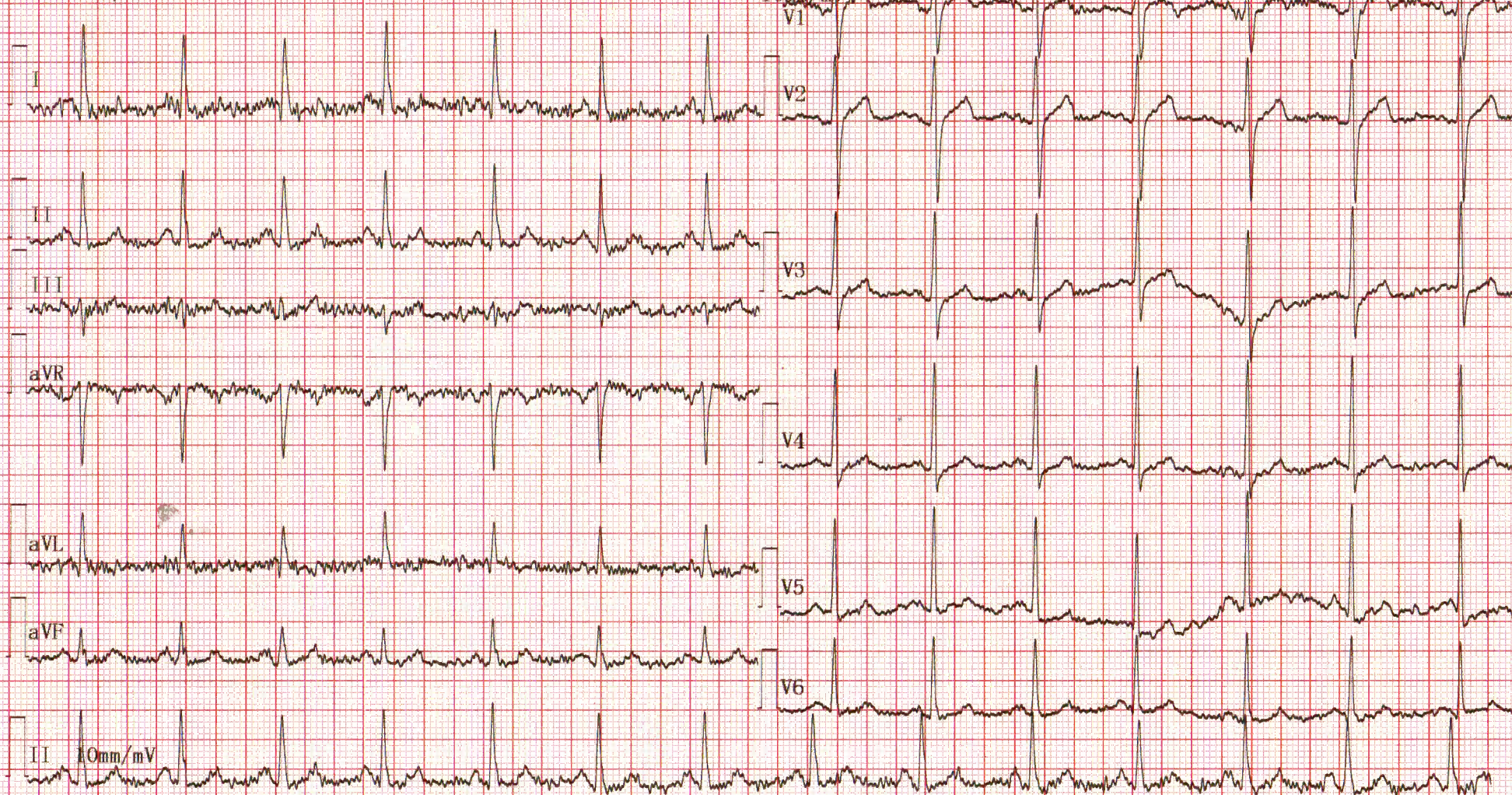
ST depression, mild high lateral myocardial ischemia,

I aVL V4 V5 V6 Abnormal T wave,

****Report need physician confirm****

Physician:

AUTO 10mm/mV



25mm/s EMC25Hz+DFT0.5Hz