

2024-02-06 11:38:54

Name : mot khotychas

Sex : Female Age : 49

Section: 1

RoomID:

BedID:

ID:

Operator: hh

Custom1:

Custom2:

Custom3:

Data for reference only:

HR bpm : 75

PR Interval ms : 201

P Duration ms : 120

QRS Duration ms : 81

T Duration ms : 243

QT/QTc ms : 391/436

P/QRS/T Axis deg : 70.0/42.1/55.7

R(V5)/S(V1) mV : 0.77/0.45

R(V5)+S(V1) mV : 1.23

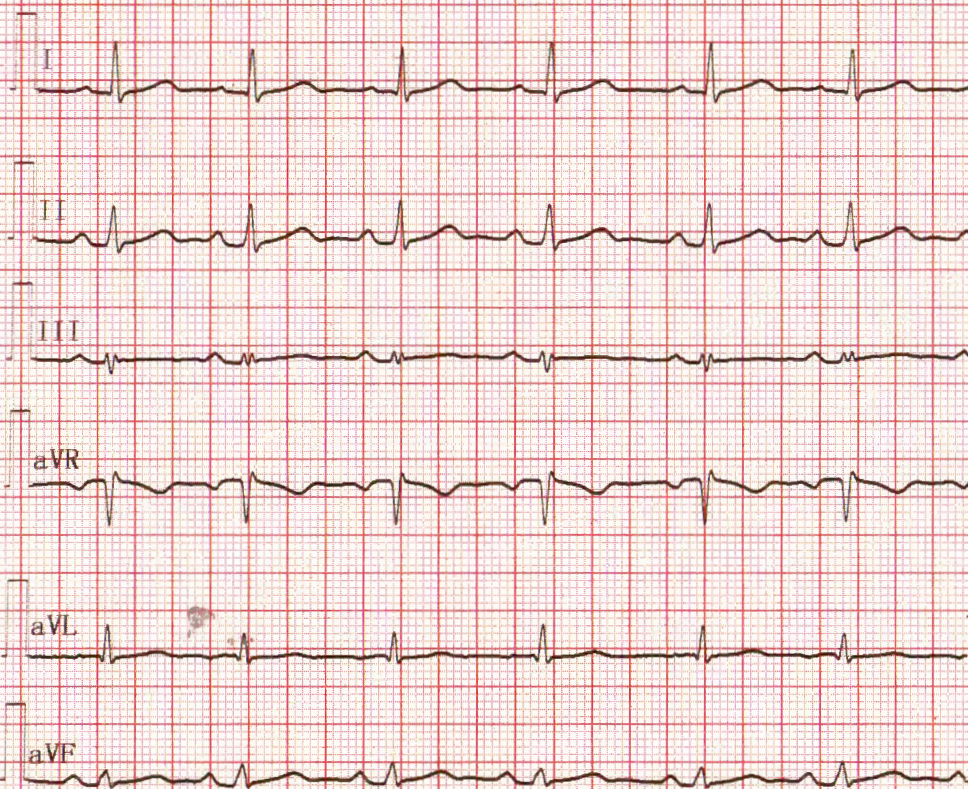
<< Conclusions >>

Cardiac electric axis normal.

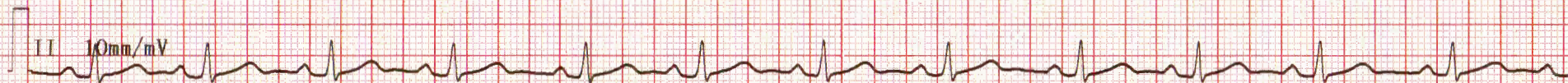
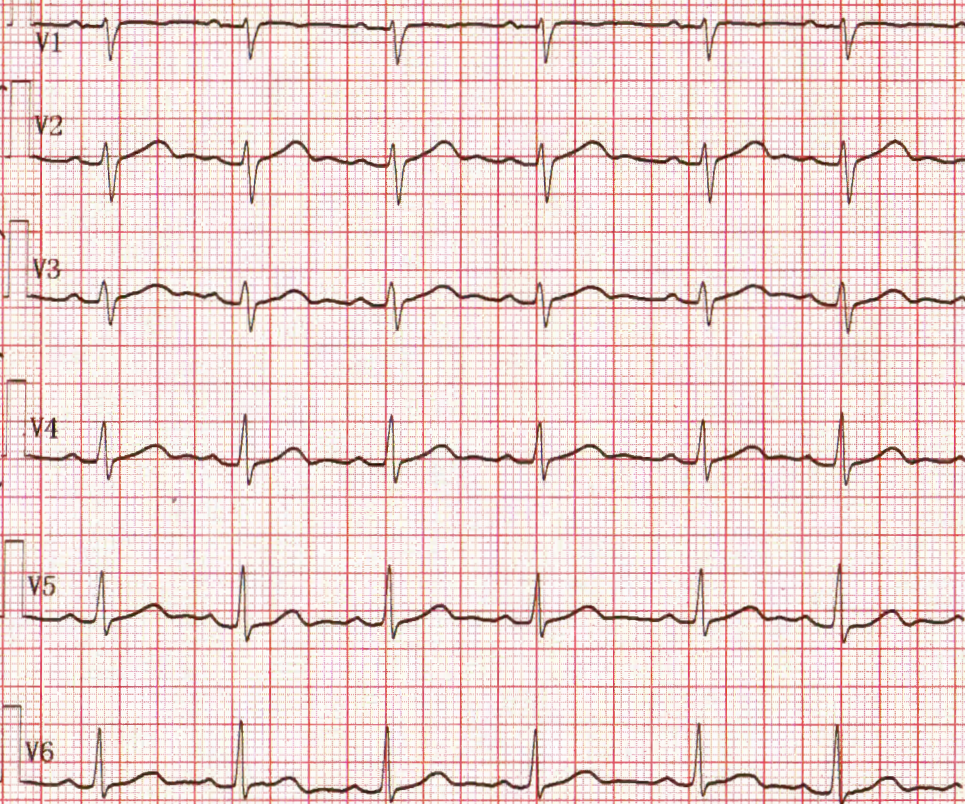
****Report need physician confirm****

Physician:

AUTO 10mm/mV



10mm/mV



25mm/s EMC25Hz+DFT0.5Hz